VERSION 1.0 31 JANUARY 2002

Evaluating Patients for Smallpox

Acute, Generalized Vesicular or Pustular Rash Illness Protocol

Chickenpox (varicella)

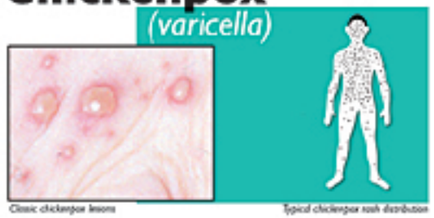

Classic chickenpox lesions — Typical chickenpox rash distribution

Images of Chickenpox (Varicella)

Healthy child with varicella — Healthy adult with varicella — Bacterial superinfection of varicella lesions

Note centripetal distribution of rash — Day 3 of rash — Lesions are in different stages of development (clock of hand)

Healthy adult with varicella — Healthy adult with varicella — Pregnant woman with varicella

Differentiating Chickenpox from Smallpox

Chickenpox (varicella) is the most likely condition to be confused with smallpox.

In chickenpox:

- No or mild prodrome
- Lesions are superficial vesicles: "dewdrop on a rose petal" (see photo at top)
- Lesions appear in crops; on any one part of the body there are lesions in different stages (papules, vesicles, crusts)
- Centripetal distribution: greatest concentration of lesions on the trunk, fewest lesions on distal extremities. May involve the face/scalp. Occasionally entire body equally affected.
- First lesions appear on the face or trunk
- Patients rarely toxic or moribund
- Rapid evolution: lesions evolve from macules => papules => vesicles => crusts quickly (<24 hours)
- Palms and soles rarely involved
- Patient lacks reliable history of varicella or varicella vaccination
- 50-80% recall an exposure to chickenpox or shingles 10-21 days before rash onset

Photo Credits: Dr. Thomas Mack, Dr. Barbara Watson, Dr. Scott A. Norton, Dr. Patrick Algaire, World Health Organization, American Academy of Pediatrics, American Academy of Dermatology

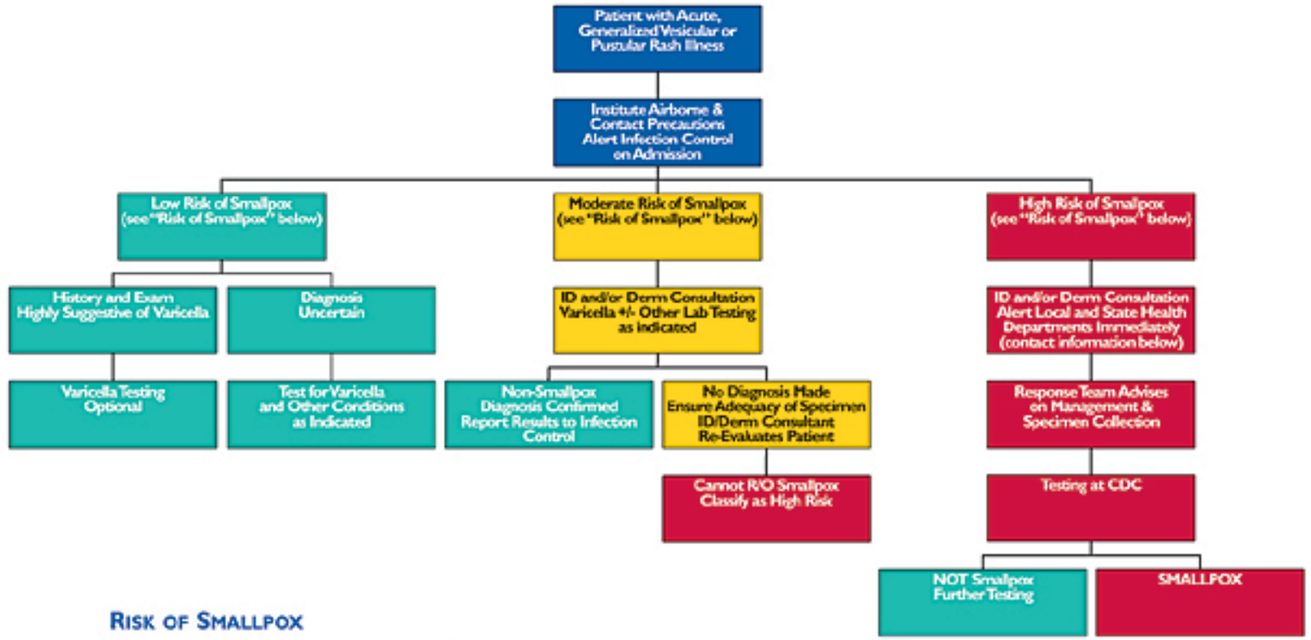

Risk of Smallpox

High Risk of Smallpox => Report Immediately

1. Febrile prodrome (defined below) **AND**
2. Classic smallpox lesion (defined below & photo at top right) **AND**
3. Lesions in same stage of development (defined below)

Moderate Risk of Smallpox => Urgent Evaluation

1. Febrile prodrome (defined below) **AND**
2. One other **MAJOR** smallpox criterion (defined below)

OR

1. Febrile prodrome (defined below) **AND**
2. ≥4 **MINOR** smallpox criteria (defined below)

Low Risk of Smallpox => Manage as Clinically Indicated

1. No febrile prodrome

OR

1. Febrile prodrome **AND**
2. <4 **MINOR** smallpox criteria (defined below)

There have been no naturally occurring cases of smallpox anywhere in the world since 1977. A high risk case of smallpox is a public health and medical emergency.

Report ALL HIGH RISK CASES immediately (without waiting for lab results) to:

1. Hospital Infection Control _____ ( ) _____-_____
   _____ ( ) _____-_____
2. _____ health department ( ) _____-_____
   ( ) _____-_____
3. _____ health department ( ) _____-_____
   ( ) _____-_____

MAJOR Smallpox Criteria

- **FEBRILE PRODROME:** occurring 1-4 days before rash onset: fever ≥101°F and at least one of the following: prostration, headache, backache, chills, vomiting or severe abdominal pain.
- **CLASSIC SMALLPOX LESIONS:** deep-seated, firm/hard, round well-circumscribed vesicles or pustules; as they evolve, lesions may become umbilicated or confluent
- **LESIONS IN SAME STAGE OF DEVELOPMENT:** on any one part of the body (e.g., the face, or arm) all the lesions are in the same stage of development (i.e., all are vesicles, or all are pustules)

MINOR Smallpox Criteria

- Centrifugal distribution: greatest concentration of lesions on face and distal extremities
- First lesions on the oral mucosa/palate, face, or forearms
- Patient appears toxic or moribund
- Slow evolution: lesions evolve from macules to papules => pustules over days (each stage lasts 1-2 days)
- Lesions on the palms and soles

Department of Health and Human Services
Centers for Disease Control and Prevention

Smallpox (variola)

Typical smallpox rash distribution — Classic smallpox lesions

Images of Smallpox

Day 3 of rash — Day 5 of rash — Day 7 of rash

On any one part of the body, all lesions are in the same stage of development

Most patients with smallpox have lesions on the palms or soles — Umbilicated lesions — Confluent lesions

Common Conditions That Might Be Confused with Smallpox

Condition	Clinical Clues
Varicella (primary infection with varicella-zoster virus)	Most common in children <10 years; children usually do not have a viral prodrome
Disseminated herpes zoster	Immunocompromised or elderly persons; rash looks like varicella, usually begins in dermatomal distribution
Impetigo (*Streptococcus pyogenes, Staphylococcus aureus*)	Honey-colored crusted plaques with bullae are classic but may begin as vesicles; regional not disseminated rash; patients generally not ill
Drug eruptions	Exposure to medications; rash often generalized
Contact dermatitis	Itching; contact with possible allergens; rash often localized in pattern suggesting external contact
Erythema multiforme minor	Target, "bull's eye", or iris lesions; often follows recurrent herpes simplex virus infections; may involve hands & feet (including palms & soles)
Erythema multiforme (incl. Stevens Johnson Syndrome)	Major form involves mucous membranes & conjunctivae; may be target lesions or vesicles
Enteroviral infection esp. Hand, Foot and Mouth disease	Summer & fall fever & mild pharyngitis 1-2 days before rash onset; lesions initially maculopapular but evolve into whitish-grey tender, flat often oval vesicles; peripheral distribution (hands, feet, mouth, or disseminated)
Disseminated herpes simplex	Lesions indistinguishable from varicella; immunocompromised host
Scabies; insect bites (incl. fleas)	Itching is a major symptom; patient is not febrile & is otherwise well
Molluscum contagiosum	May disseminate in immunosuppressed persons

For more information, please go to the CDC website http://www.cdc.gov/nip/smallpox and http://www.bt.cdc.gov/Emergency/Contacts/index.asp